Non-IPF Interstitial Lung Disease Therapeutic Options

Authors:
Namrata B. Patel, MD
Clinical Director, Interstitial Lung Disease Program
Associate Professor of Clinical
University of Pennsylvania

Rupal Shah, MD MSCE
Associate Professor, Medicine
University of California, San Francisco

Editor:
Stacey Kassutto, MD, MA
Director, IM Residency Simulation Education
Core Faculty, Pulmonary Fellowship Education
Associate Director, Medical Education
Leadership Track
Assistant Professor of Clinical
Medicine
University of Pennsylvania

Section Editors:
Abhaya Trivedi, MD
Associate Program Director
Assistant Professor
Rush University Medical Center

Avraham Z. Cooper, MD
Assistant Program Director
Assistant Professor - Clinical
The Ohio State University

Learning Objectives:

1. Describe the medical treatment options for various interstitial lung diseases
2. Review drug initiation and monitoring
3. Discuss additional non-pharmacologic therapeutic considerations

© 2022 Association of Pulmonary and Critical Care Medicine Program Directors

Scenario 1:
A 43-year-old man presented with 6 months of progressive dyspnea on exertion without associated cough, fevers, chills, chest pain, join pains, skin changes, abdominal pain, nausea, or diarrhea. He did endorse 10 lbs. weight loss in the last 6 months. He was previously healthy and denies any prior surgeries. He currently takes no medications. He is married with 2 children. He works in an auto body shop but does not have any contact with brakes. He denies any asbestos exposure or dust fumes. His occupational history is also notable for prior minimal work in sandblasting, farming, and construction. He is a lifetime non-smoker. He denies any use of drugs or alcohol. There is no family history of lung disease. His exam is notable for rapid shallow respirations and bibasilar crackles.

His testing is notable for
PFT:
FEV1 of 1.67 (54%)
FVC 1.78 (50%)
DLCO 45%

6-minute walk test – Oxygen saturation of 91% on room air at rest, and requires 2LPM with exertion. Imaging is shown below.

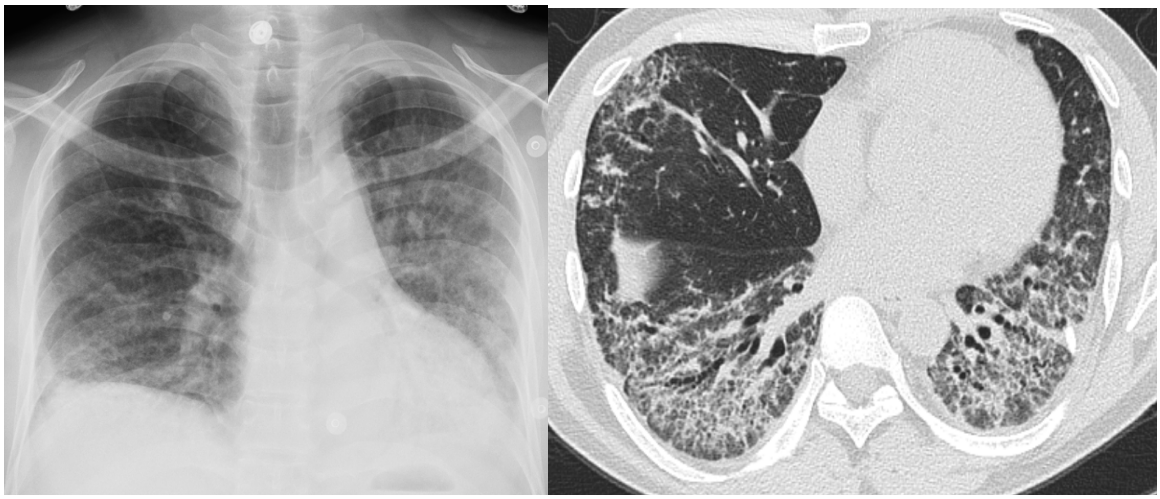

He has negative autoimmune serologies and a negative hypersensitivity panel. He undergoes bronchoscopy with BAL that is negative for PCP and shows a lymphocytosis. He ultimately undergoes a VATS biopsy that is consistent with nonspecific interstitial pneumonitis (NSIP).

<u>Question 1:</u> What are the treatment options for this patient with NSIP?

Corticosteroids are often the mainstay of initial treatment. Typical dosing of prednisone is 0.5-1.0 mg/kg daily tapered to 30-40 mg daily at 3 months. We recommend a slow taper over time. In patients who are acutely ill with respiratory failure in the hospital, we also consider pulse methylprednisolone. Steroids have been shown to be effective. In one study of 35 patients, 86% had a >10% improvement in their FVC. 53% had a >10% improvement and 28% stabilized. There is however a chance of relapse with steroid taper. In one study relapse rate was 25% and was associated with a shorter duration for therapy and a lower initial steroid dose as well as a positive ANA.

© 2022 Association of Pulmonary and Critical Care Medicine Program Directors

<u>Question 2:</u> What are some steroid sparing agents to consider for treating NSIP?

Studies regarding best treatment options in NSIP are limited and mostly small case series. Preference for steroid sparing agents will vary by practice. Mycophenolate (particularly in scleroderma, polymyositis and dermatomyositis) or azathioprine are most commonly used. Cyclophosphamide should also be considered. A study of 54 patients with biopsy proven or suspected NSIP received cyclophosphamide. This was associated with disease stability at 6 months and was generally well tolerated. PFTs also generally improved. (Corte TJ, et al. Sarcoidosis Vasc Diffuse Lung Dis, 2009).

Drug	Dosing	Baseline Labs	Monitoring	Side Effects	Therapeutic Effect
Azathioprine (Imuran)	2-3 mg/kg daily; start at 50 mg and increase every 3 weeks by 50 mg daily (max dose 150-200 mg daily)	CBC, LFT, TMPT	CBC and LFT after each dose increase. Once at maintenance dose, CBC and LFT every month x 3 then every other month.	Abnormal LFTs, leukopenia, GI upset, flu-like symptoms, pancreatitis, hypersensitivity, infection, malignancy	~3 months
Mycophenolate (Cellcept)	500 mg BID and increase every 3 weeks by 500 mg BID (max dose 1.5g BID)	CBC	CBC every month x 12, then every other month	GI upset, marrow suppression, infection, PML, malignancy; avoid during pregnancy/lactation	~2-3 months
Cyclophos-phamide (Cytoxan)	Variable, recommend 500-750 mg/m2 monthly, oral 2mg/kg/day	CMP, CBC, UA	CBC, CMP, and UA 10 - 14 days post infusion	Abnormal LFTs, leukopenia, cystitis and bladder cancer, infection, GI upset, gonadal toxicity, infertility, malignancy	~2-3 months

© 2022 Association of Pulmonary and Critical Care Medicine Program Directors

<u>Question 3:</u> Because his symptoms worsened when attempting to wean prednisone, you started him on CellCept. He has stability for several months, but he returns for follow up with worsening dyspnea, hypoxemia with exertion and worsening pulmonary function. You repeat a high-resolution CT chest that shows progression of fibrosis. How would this change your management?

Nintedanib has been studied in progressive fibrotic lung disease in non IPF patients (INBUILD). Patients enrolled in the trial had to meet one of the following criteria for progression of ILD within 24 months prior to screening: progression of fibrosis and worsening respiratory symptoms on high resolution CT, decline in FVC of 10%, decline in FEV1 by 5-10% or worsening of respiratory symptoms or an increased extent of fibrosis. Patients who received nintedanib had a slower decline in lung function compared to placebo (80 mL vs 188 mL) (Flaherty et al NEJM, 2019).

Scenario 2:
A 50-year-old man who was otherwise well until March 2014 when he started having joint pains and fatigue presents for evaluation. One month after his initial symptoms began, he started having breathlessness when moving the lawn, hand swelling, dry hands with cracking and Raynaud's. His physical exam was notable for Gottron's papules, dry tight skin on his hands, facial erythema and shawl sign. His HRCT is shown below.

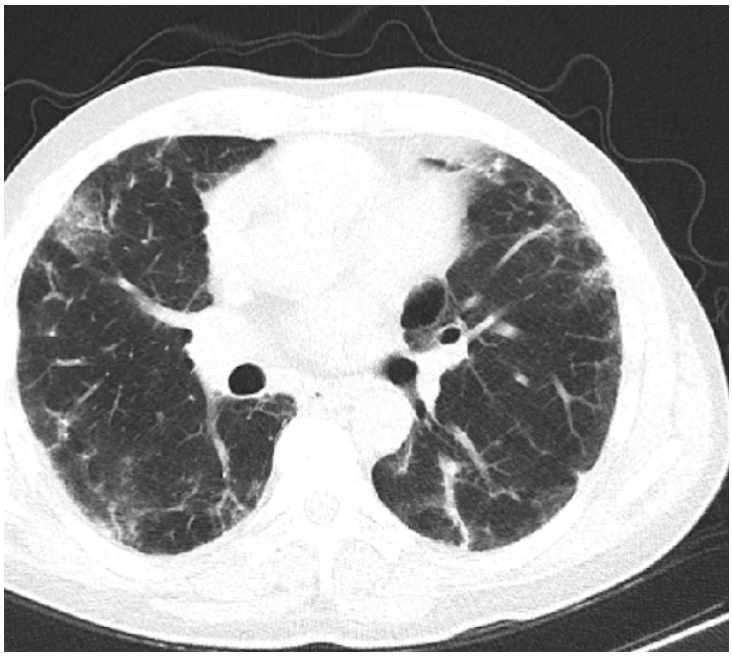

After review at your multidisciplinary interstitial lung disease conference, the radiologic diagnosis is thought to be NSIP. He was ultimately diagnosed with dermatomyositis and CTD-ILD.

His PFTs are notable for moderate restriction with FEV1 62%, DLCO 55% predicted. His ambulatory saturation nadir on his 6MWT was 93% on room air.

© 2022 Association of Pulmonary and Critical Care Medicine Program Directors

<u>Question 4:</u> What are the treatment options for ILD related to myositis?

Regardless of radiological or pathological pattern, the first line treatment of ILD related to myositis is prednisone with a steroid sparing agent, most commonly mycophenolate or azathioprine (with cyclophosphamide sometimes used). A retrospective review of 125 patients with CTD-ILD was performed in patients treated with mycophenolate. Thirty-two of these patients had polymyositis or dermatomyositis. Patients with a non-UIP pattern had improvement in their FVC and DLCO and patients with CTD and UIP pattern had stability in their lung function. (Fischer et al J Rheumatology 2013). Azathioprine has been demonstrated to have similar efficacy based on case series (Marie et al Arthritis Care Res 2013).

However, if patients are progressing despite first line therapy, there are further options including:

a. Tacrolimus (calcineurin inhibitor): Twice a day medication, with goal 12-hour trough 6-12. Needs to be closely monitored until therapeutic range is achieved. Side effects include nephrotoxicity, neuropathy, and diabetes

   A study of 13 patients with anti-synthetase syndrome on tacrolimus demonstrated significant improvement in pulmonary function. 10/13 also had improvement in muscle symptoms

b. Rituximab (anti -D20 ab): Given IV, typically 2 doses 1 week apart, then every 6 months. Generally well tolerated, but side effects include infusion reaction, cytopenia, hypogammaglobulinemia, and infection (in particular, all patients need hepatitis serologies prior to starting).

   There are several case reports and case series supporting use of rituximab. In a randomized, placebo phase (rituximab early vs. rituximab late) of refractory myositis, 83% of patients had improvement in muscle symptoms, although they did not study pulmonary function as an outcome (Oddis et al. Rheumatology 2013)

The patient returns for follow up with progressive dyspnea, but CT chest shows stability in lung disease. Repeat pulmonary function is stable, except DLCO has declined significantly. You obtain an echocardiogram that shows new RV failure with an elevated estimated pulmonary artery systolic pressure.

<u>Question 5:</u> While this patient may have combined Group 1 (CTD) and Group III (ILD) pulmonary hypertension, what therapeutic options should be considered for pulmonary hypertension related to ILD?

In patients with pulmonary hypertension due to interstitial lung disease, patients treated with inhaled treprostinil compared to placebo had an increase in 6-minute walk distance from baseline at week 16. Additionally, there was a significant reduction in NT-proBNP levels in patients treated with inhaled treprostinil compared to an increase in levels in the placebo group (Waxman et al. NEJM 2021).

© 2022 Association of Pulmonary and Critical Care Medicine Program Directors

<u>Question 6:</u> What are treatment options for scleroderma related ILD?

Two randomized controlled trials have evaluated therapy for scleroderma related ILD: SLS-1 and 2.

SLS-1 (Tashkin, et al 2006) compared cyclophosphamide for 1 year vs. placebo, and found an improvement in 2.5% of predicted FVC favoring cyclophosphamide, although the effect was lost once the drug was stopped.

SLS-2 (Tashkin, et al 2016) compared cyclophosphamide vs. mycophenolate mofetil. Both drugs had equal efficacy in improving FVC, dyspnea and skin thickness. However, cyclophosphamide was associated with greater withdrawal from the study due to side effects.

More recently, nintedanib and tocilizumab have been studied in scleroderma-ILD.

The nintedanib trial in systemic sclerosis (SENSCIS) included 576 patients, about half of which were already on mycophenolate. Patients had been diagnosed within the last 7 years and had at least 10% fibrosis on HRCT. Patients were treated with a nintedanib 150 mg twice-daily vs placebo. The annual rate of decline of FVC was lower in the nintedanib group compared to placebo– 52 mL vs 93 mL per year. This effect was more pronounced in the subgroup of patients who were not already on mycophenolate (Distler et al. NEJM 2019).

Tocilizumab is now FDA approved for scleroderma-ILD based on the FocuSSed trial (Khanna et al, Lancet Respiratory 2020), an RCT that that assessed the safety and efficacy of tocilizumab to treat skin fibrosis and systemic-sclerosis associated ILD. Patients received tocilizumab injections of 162 mg weekly or placebo. The tocilizumab group had less decline in FVC % predicted at 48 weeks compared to placebo (14 mL vs 255 mL). There was no change in skin fibrosis with tocilizumab.

© 2022 Association of Pulmonary and Critical Care Medicine Program Directors

Scenario 3:
A 65-year-old woman presents with shortness of breath and cough. She had a CXR and was told that she had a viral infection. However, her symptoms persisted, so she had another CXR and HRCT (see images below). She was diagnosed with IPF with moderate restriction and started on pirfenidone. When she presents to you for a second opinion months later, she feels much better. She tells you that she owns a plant nursery and her symptoms are temporally associated with peat moss deliveries. She undergoes surgical lung biopsy that demonstrates extensive interstitial fibrosis and patchy inflammation, numerous fibroblast foci and non-necrotizing granulomas in a bronchovascular distribution, most prominent in the upper lobes. These features are suggestive of hypersensitivity pneumonitis.

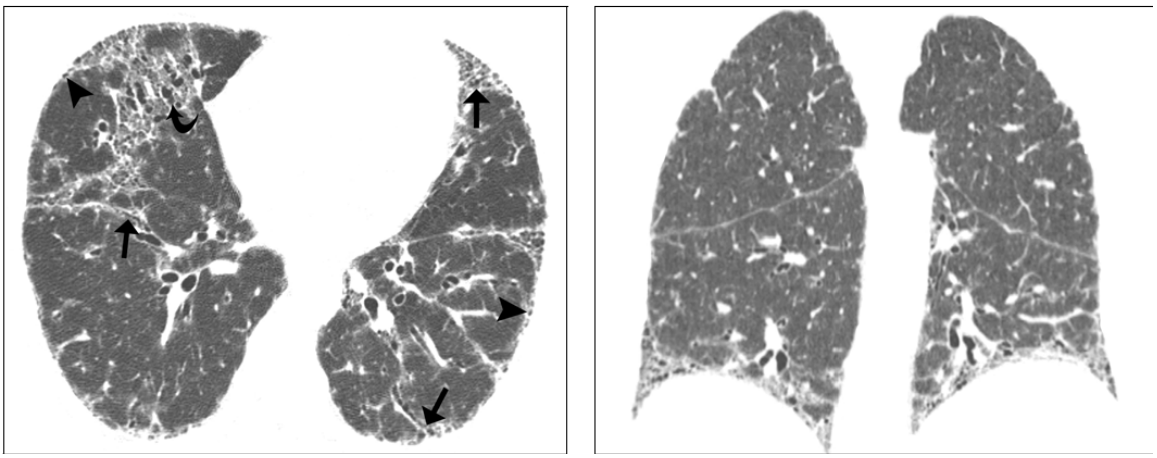

Images borrowed from Silva CI, et al. AJR 2007.

<u>Question 7:</u> What factors do you consider in the diagnosis of hypersensitivity pneumonitis?

An international survey was conducted to obtain expert opinion regarding the diagnostic criteria for chronic hypersensitivity pneumonitis. Highest importance was given to identification of causative antigen, time relation between exposure and disease, mosaic attenuation on chest imaging, and poorly formed non-necrotizing granulomas on pathology. Additionally, BAL results of lymphocytosis > 20% can often be seen with HP. (Morisset et al AJRCCM 2018).

<u>Question 8:</u> What are the therapeutic options for management of hypersensitivity pneumonitis (HP)?

The mainstay of therapy is removal of the antigen followed by thorough cleaning of the house or workplace. Some patients, such as those with inflammatory features on chest CT (e.g. ground glass opacities), bronchoscopy (lymphocytosis on BAL), or biopsy (significant interstitial or granulomatous inflammation on histopathology), may benefit from immunosuppression. For those patients that are treated, initial therapy involves corticosteroids at 0.5-1mg/kg, tapered over months. If patients cannot tolerate high dose corticosteroids, fail attempts at tapering, or do not respond to initial therapy then steroid sparing agents can be considered. In a retrospective review of 70 patients with HP, both mycophenolate and azathioprine were associated with increased DLCO after 1 year, although no improvement in FVC was seen (Morisset et al Chest, 2017).

© 2022 Association of Pulmonary and Critical Care Medicine Program Directors

<u>Question 9:</u> For patients on long-term corticosteroid therapy, when should you start pneumocystis prophylaxis?

Typically PJP prophylaxis should be initiated if patients are receiving prednisone 20mg daily or more (or equivalent dosing of another corticosteroid) on a long-term basis. For patients on another immunosuppressant in addition to prednisone, even if the prednisone dose is less than 20 mg daily, PJP prophylaxis should be considered. First line therapy is with trimethoprim-sulfamethoxazole. Dapsone (once G6PD deficiency is excluded), atovaquone or inhaled pentamidine are other options.

References:

- Distler et al. Nintedanib for Systemic Sclerosis – Associated Interstitial Lung Disease. NEJM 2019; 380: 2518-28.
- Flaherty et al. Nintedanib in Progressive Fibrosing Interstitial Lung Diseases. NEJM 2019; 381: 1718-1727.
- Fischer et al. Mycophenolate Mofetil Improves Lung Function in Connective Tissue Disease-associated Interstitial Lung Disease. J Rheumatology 2013: 40: 640-646.
- *Marie et al.* Interstitial lung disease in anti-Jo-1 patients with antisynthetase syndrome.
- *Arthritis Care Res (Hoboken). 2013 May; 65(5):800-8.*
- Khanna et al. Tociluzmab in systemic sclerosis: a randomized double-blind, placebo-controlled, phase 3 trial. Lancet Respiratory Medicine 2020: 10: 963-974.
- Morisset, et al *Use of mycophenolate mofetil or azathioprine for the management of chronic hypersensitivity pneumonitis* Chest 2017
- Morisset et al. Identification of Diagnostic Criteria for Chronic Hypersensitivity Pneumonitis: An International Modified Delphi Survey. Am J Respir Crit Care Med 2018; 8: 1036-1044.
- Oddis, et al Rituximab in the Treatment of Refractory Adult and Juvenile Dermatomyositis and Adult Polymyositis: A Randomized, Placebo-phase Trial. Arthritis Rheumatology 2013
- Tashkin, et al Mycophenolate mofetil versus oral cyclophosphamide in scleroderma-related interstitial lung disease (SLS II): a randomized controlled, double-blind, parallel group trial. Lancet Resp Med 2016.
- Tashkin DP, Elashoff R, Clements PJ, Goldin J, Roth MD, Furst DE, *et al*.; Scleroderma Lung Study Research Group. Cyclophosphamide versus placebo in scleroderma lung disease. *N Engl J Med* 2006;354:2655–2666.
- Wilkes MR Treatment of antisynthetase-associated interstitial lung disease with tacrolimus. Arthritis Rheumatology; August 2005.
- Cottin, V et al Nonspecific interstitial pneumonia. Individualization of a clinicopathologic entity in a series of 12 patients. <u>Am J Respir Crit Care Med.</u> 1998 Oct;158(4):1286-93.
- Waxman et al. Inhaled Treprostinil in Pulmonary Hypertension Due to Interstitial Lung Disease. NEJM 2021; 384: 325-334.
- Silva CI, Churg A, Muller NL. Hypersensitivity Pneumonitis: Spectrum of High-Resolution CT and Patholgic Findings. AJR 2007; 188: 334-344.

© 2022 Association of Pulmonary and Critical Care Medicine Program Directors