Association of Pulmonary and Critical Care Medicine Program Directors

Asthma Mimics

Author Judd Flesch, MD
Editor Stacey M. Kassutto, MD

Literature review current through June 2023
Last updated June 2023

Section Editors
2023 Mateusz Tkacz, MD
Abhaya Trivedi, MD
Michael Powers, MD
Laura Hinkle, MD, MEd
2021 Abhaya Trivedi, MD
Avraham Z. Cooper, MD

Educational Objectives:

1. Review the diagnostic criteria for asthma.
2. Recognize signs and symptoms that suggest an asthma mimic.
3. Develop a diagnostic plan for common conditions that mimic asthma.

Scenario:
Mrs. H is a 57-year-old woman with a history of asthma and CHF with preserved ejection fraction who presents for consultation due to worsening shortness of breath. She reports having asthma for many years with occasional ED visits but no prior hospitalizations, and typically has one exacerbation per year on average. However, her breathing has worsened for the past year, and she has experienced significant exertional dyspnea in addition to a chronic cough productive of clear sputum. She feels that her breathing is stable at home, but her symptoms get worse when she goes out. She takes albuterol and has been on prednisone for much of the past year without relief. She smoked 1 pack of cigarettes daily for 25 years but quit two months ago. On exam, her BMI is 30.4, her O2 sat is 97% on RA, and she has audible wheezing. No PFTs are available.

Question 1: What are some clues in her presentation that asthma may not be the only explanation for Mrs. H's respiratory symptoms?

Asthma Definition: "Common chronic disorder of the airways complex and characterized by variable and recurring symptoms, airflow obstruction, bronchial hyper-responsiveness, and underlying inflammation."[1]

Diagnosis:
- Episodic symptoms of airflow obstruction or airway hyper-responsiveness
- Airflow obstruction is at least partially reversible
- Alternative diagnoses are excluded

Abnormal or unresolved issues for our patient:
- Chronic but not episodic symptoms
- Productive cough
- Smoking history
- Audible wheeze

© 2023 Association of Pulmonary and Critical Care Medicine Program Directors

Clinical Features Favoring and Not Favoring Asthma in Those with Episodic Symptoms[9]:

Favoring:

- At least two of the following: wheeze, breathlessness, chest tightness, cough (+/- sputum). Especially if: worse at night or early morning, symptoms w/exercise, exposure to allergens, or cold air, symptoms following ASA or B-blocker use
- History of atopy
- Widespread wheeze on exam
- Low FEV1 or peak expiratory flow that is otherwise unexplained
- Peripheral eosinophilia otherwise unexplained

Not Favoring:

- Prominent dizziness, lightheadedness or peripheral tingling
- Chronic productive cough without wheezing or breathlessness
- No wheezing on exam while symptomatic
- Voice disturbance
- Significant smoking history (20+ pack years)
- Cardiac disease
- Normal peak expiratory flows or spirometry while symptomatic

An important note: studies have shown poor inhaler technique can lead to poor asthma outcomes. It is important to confirm that the patient is properly using their inhaler before considering other underlying causes.[11]

Question 2: What common conditions might be mistaken for asthma in this patient, and what initial testing might you order?

COPD is probably the most common condition that is confused with asthma. Prior asthmatics who are long-term smokers are also at risk for developing COPD.

Tests that can help guide your diagnosis include:

- Chest imaging
- Pulmonary function testing, including pre- and post-bronchodilator spirometry
- CBC with differential to look for eosinophilia

Bronchodilator reversibility is more characteristic of asthma than COPD. However, partial reversibility can be seen in COPD, uncontrolled asthma, or chronic asthma with airway remodeling.

Scenario continued:
Her chest x-ray is completed and you note clear lungs with no evidence of hyperinflation. Her spirometry demonstrates an FVC of 1.36 L (56% predicted), FEV1 0.95L (50% predicted), and FEV1/FVC ratio 70. Her SVC was 1.54 L (64% predicted) and her FEV1/SVC ratio was 61%. The tech noted the following: "Albuterol sulfate nebulizer was given but post-bronchodilator studies were not done as the patient had anxiety about getting stuck in traffic, so she asked to stop the test and get on the road." You note that there is flattening of the inspiratory limb of the flow volume loop.

© 2023 Association of Pulmonary and Critical Care Medicine Program Directors

Question 3: Does her spirometry raise concern for any particular conditions that may mimic asthma?

Differential Diagnosis of Vocal Cord Disorders Mimicking Asthma2	
Irritants	Extrinsic: Chemicals; Intrinsic: GERD, rhinitis, post-nasal drip
Laryngospasm	airway manipulation (bronchoscopy, intubation), IgE mediated, nocturnal aspiration
Neurogenic	movement disorders, adductor laryngeal breathing
Psychogenetic	Somatoform disorder, conversion disorder, psychiatric illness, abuse, anxiety, stress
Supraglottic	Exercise-related supraglottic closure
Vocal cord paresis/paralysis	intubation, head/neck malignancy, chest surgery, idiopathic

Question 4: What steps would you take to evaluate her for VCD?

Evaluation of Vocal Cord Dysfunction		
Clinical Signs/Symptoms	**Laryngoscopy**	**PFT Findings**
- Prolonged symptoms - Intermittent episodes - Dyspnea - Stridor / upper airway wheeze - Reproducible inciting factor	- Adduction of VCs (inspiratory or both) - > 50% closure - Intermittent - "Posterior chinking"	- No BD response - Negative bronchoprovocation - Flattened inspiratory limb of flow-volume loop

Examples of Variable and Fixed Obstruction on Flow Volume Loops

Fixed Obstruction	Variable Extrathoracic Obstruction	Variable Intrathoracic Obstruction

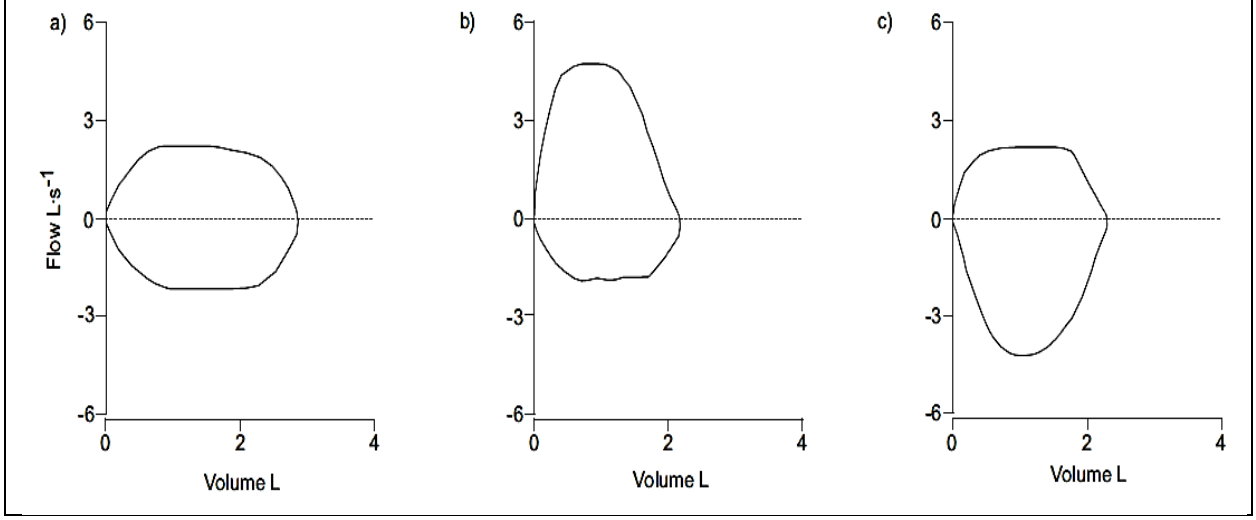

© 2023 Association of Pulmonary and Critical Care Medicine Program Directors

Scenario continued:
You refer her to ENT and a laryngoscopy is performed. There is no abnormal vocal cord motion even though she is audibly wheezing during the study.

Question 5: What else should you consider, given the audible wheeze?

Consider evaluation for subglottic airway obstruction.

Scenario continued:
Her previous flow-volume loop was potentially truncated on the inspiratory limb, so you order a CT of the chest with inspiratory and expiratory views. The report notes that the airway caliber is normal, and there is no significant reduction in caliber on expiration. In the interim, you advise her to taper her steroids and start a high-dose ICS/LABA. She returns to see you and tells you her symptoms are unchanged, except she thinks her cough has worsened slightly, and she is coughing up balls of mucus.

Question 6: What other diagnosis should you consider, and what diagnostic workup do you recommend?

Refractory asthma and a productive cough should raise the possibility of allergic bronchopulmonary aspergillosis (ABPA). ABPA is caused by hypersensitivity to *Aspergillus fumigatus* and is a complication of asthma and cystic fibrosis. Some estimates suggest it complicates up to 6% of chronic asthma[10].

The diagnostic criteria for ABPA are as follows:[3]

1. Predisposing conditions: asthma or cystic fibrosis

2. Obligatory criteria (both **MUST** be present)
    a. Positive type I skin test for *Aspergillus fumigatus* or serum IgE levels against *Aspergillus fumigatus* (>0.35 kU/L)
    b. IgE levels > 1000 IU/mL*
3. Other criteria (must have 2 of 3)
    a. Serum precipitins OR IgG antibodies against *A. fumigatus*
    b. Absolute eosinophil count > 500 cells/microL
    c. Radiographic opacities consistent with ABPA

* If all other criteria are present, IgE level > 500 IU/mL is acceptable

Radiographic features include:

- **Central mucus plugging** (finger-in-glove)
- Consolidation
- **Central bronchiectasis**
- Pleuropulmonary fibrosis

© 2023 Association of Pulmonary and Critical Care Medicine Program Directors

Mucus plugging with associated consolidation.

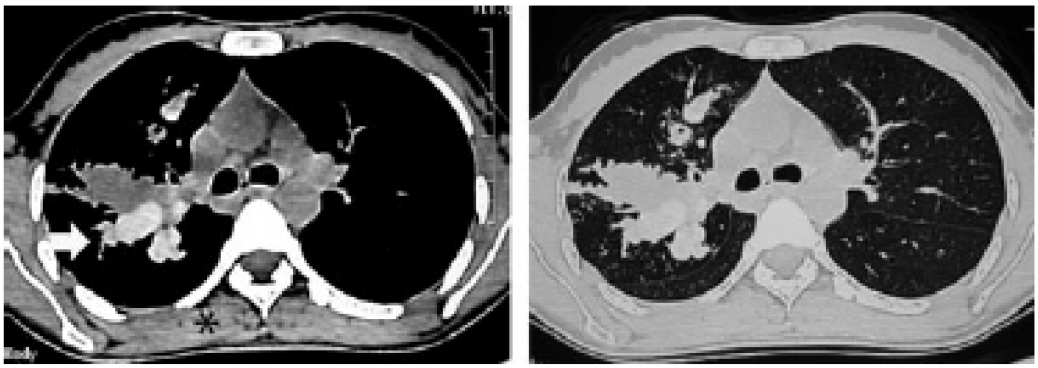

Central bronchiectasis (images reproduced from Agarwal, et al.[3])

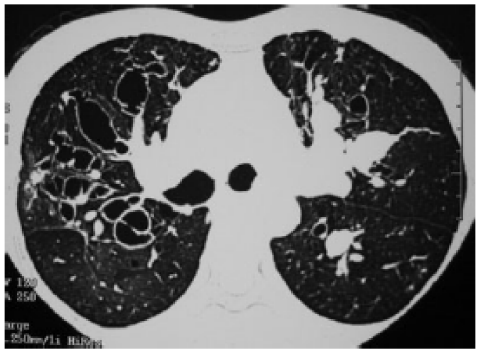

Scenario continued:
You order a CBC with differential IgE level, hypersensitivity pneumonitis panel (for the serum IgG), refer her for skin testing, and a CT scan.

Question 7: While you are busy ordering her studies, she asks how you would treat ABPA if she had it. What do you tell her?

1. Corticosteroids are the mainstay of the initial treatment of ABPA with mucoid impaction or lung function abnormalities.

   A case series suggested that a longer duration of treatment with high steroid doses is associated with higher remission rates and less steroid-dependent disease. The starting dose in the case series was 0.75 mg/kg, tapered every six weeks, with total duration of 6-12 months.[4]

2. Antifungals should be considered in some circumstances. A randomized trial published in 2000 examined a course of itraconazole 200 mg twice daily versus placebo in patients with 'steroid-dependent' ABPA.[6] There was a significant increase in treatment response in patients taking itraconazole versus placebo.

© 2023 Association of Pulmonary and Critical Care Medicine Program Directors

TABLE 5. RATES OF RESPONSE OVERALL AND ACCORDING TO SEX, AGE, AND BASE-LINE CORTICOSTEROID DOSE.*

VARIABLE	ITRACONAZOLE GROUP	PLACEBO GROUP	P VALUE
	no. with response/total no.		
Overall response	13/28	5/27	0.04
Decrease in corticosteroid dose	17/22	14/25	
Decrease in total IgE	15/25	11/25	
Increase in exercise tolerance	7/21	4/21	
Improvement in ≥1 pulmonary-function tests	15/24	11/24	
Resolution or absence of characteristic pulmonary infiltrates†	18/22	18/23	
Sex‡			
Male	5/10	3/17	
Female	8/16	2/8	
Age			
≥50 yr	8/12	3/14	0.045
<50 yr	5/16	2/13	
Base-line dose of prednisone or equivalent			
≤12.5 mg/day	6/10	3/15	
>12.5 mg/day	5/16	2/11	

Results of Outcomes in Double Blind Phase of Itraconazole Trial for Treatment of ABPA. Taken from Stevens et al. *N Engl J Med*. 2000;342:756-62.

3. Inhaled corticosteroids are often used during and after steroid tapers. Itraconazole can decrease steroid metabolism.

4. Omalizumab does have limited evidence of efficacy (off-label use)
    a. An open-label study evaluating adult ABPA patients without CF treated with omalizumab showed a decrease in steroid use and fewer exacerbations compared to the year before treatment.[7]

Scenario continued:
Her studies return and are notable for the following: absolute eosinophil count of 1200, IgE 482, but a negative serum *A. fumigatus* antibody and non-reactive skin testing to *A. fumigatus*. She has not yet had her CT scan due to insurance pre-authorization issues.

Question 8: Does she have ABPA?

No – the negative skin testing rules it out.

© 2023 Association of Pulmonary and Critical Care Medicine Program Directors

Question 9: She does have eosinophilia. What conditions should you consider that cause eosinophilia and pulmonary disease?

Disorders Causing Eosinophilia	Additional Diagnostic Testing to Consider
Inflammatory Conditions	
Eosinophilic granulomatosis with polyangiitis (EGPA)	ANCA
ABPA	Aspergillus skin testing, IgE, antibodies
Idiopathic acute eosinophilic pneumonia	BAL
Chronic eosinophilic pneumonia	BAL, TBBx, surgical lung biopsy
Hypereosinophilic bronchiolitis	Surgical lung biopsy
Infections	
Loffler's syndrome: Ascaris, Hookworm, Strongyloides	Antibody ELISA testing Fleeting imaging abnormalities
Parenchymal invasion: Paragonimiasis	Antibody ELISA testing
Hematogenous seeding: includes Schistosomiasis, disseminated Strongyloides	Antibody ELISA testing
Endemic mycoses: histoplasmosis, blastomycosis, coccidiomycosis	Antigen and antibody testing, BAL cultures
Drugs and toxins	
Can range between asymptomatic pulmonary infiltration with eosinophils to DRESS syndrome; NSAIDs and some antibiotics including: nitrofurantoin, minocycline, daptomycin	
Inhalation of cocaine, marijuana, or heroin Significant exposure to dust and smoke	

Scenario continued:
Her CT scan demonstrates some areas of air trapping with tiny, peripheral-predominant nodules.

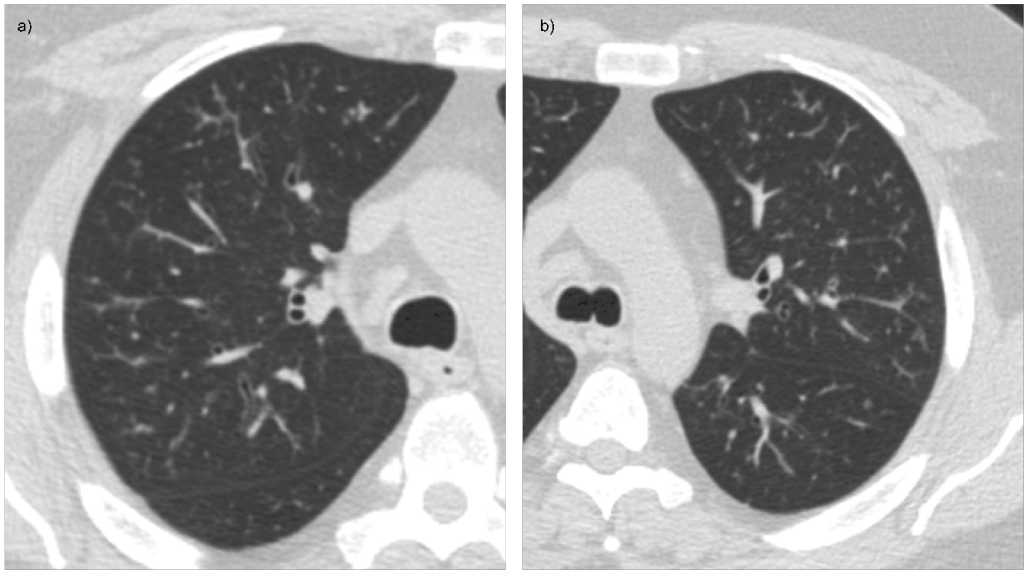

© 2023 Association of Pulmonary and Critical Care Medicine Program Directors

Question 10: Which uncommon diagnosis should you consider?

Hypereosinophilic Obliterative Bronchiolitis is a rare condition with the following diagnostic characteristics:[7]

- Peripheral eosinophilia with AEC > 1000 and/or BAL eosinophilia > 25%
- Airflow obstruction not improved by a prolonged course of inhaled bronchodilator and corticosteroid therapy
- Characteristic signs of bronchiolitis on HRCT imaging and/or lung biopsy

Case series descriptions note improvement with prolonged courses of systemic corticosteroids.

References:

1. EPR – 3. Expert panel report 3: guidelines for the diagnosis and management of asthma. NIH Publication No.07-4051. Bethesda, MD: U.S. Department of Health and Human Services; National Institutes of Health; National Heart, Lung, and Blood Institute; National Asthma Education and Prevention Program, 2007.
2. Morris MJ, Kent CL. Diagnostic criteria for the classification of vocal cord dysfunction. *Chest.* 2010;138:1213-23.
3. Agarwal R, Chakrabarti A, Shah A, Gupta D, Meis JF, Guleria R, et al. Allergic bronchopulmonary aspergillosis: review of literature and proposal of new diagnostic and classification criteria. *Clin Exp Allergy*. 2013;43:850-73.
4. Stevens DA, Schwartz HJ, Lee JY, Moskovitz BL, Jerome DC, Catanzaro A, et al. A randomized trial of itraconazole in allergic bronchopulmonary aspergillosis. *N Engl J Med*. 2000;342:756-62.
5. Agarwal R, Gupta D, Aggarwal AN, Behera D, Jindal SK. Allergic bronchopulmonary aspergillosis: lessons from 126 patients attending a chest clinic in north India. Chest 2006;130:442–8.
6. Cotton, V. Eosinophilic Lung Diseases. *Clinics in Chest Medicine*. 2016; 37: 535-556.
7. Tillie-Leblond I, Germaud P, Leroyer C, Tetu L, et al. Allergic bronchopulmonary aspergillosis and omalizumab. Allergy 2011; 66: 1252-1259.
8. Cordier JF, Cottin V, Khouatra C, Revel D, Prouse C, Freymond N, et al. Hypereosinophilic obliterative bronchiolitis: a distinct, unrecognized syndrome. *Eur Respir J*. 2013;41:1126-34.
9. Kaplan AG, Balter MS, Bell AD, Kim H, McIvor RA. Diagnosis of asthma in adults. *Canadian Medical Association Journal*. 2009;181(10):E210-E220. doi:10.1503/cmaj.080006
10. Shah A, Panjabi C. Allergic bronchopulmonary aspergillosis: A perplexing clinical entity. *Allergy, Asthma &Immunology Research*. 2016;8(4):282-297. doi:10.4168/aair.2016.8.4.282
11. Gherasim A, Dao A, Bernstein JA. Confounders of Severe asthma: Diagnoses to consider when asthma symptoms persist despite optimal therapy. *World Allergy Organization Journal*. 2018;11(1):29. doi:10.1186/s40413-018-0207-2

© 2023 Association of Pulmonary and Critical Care Medicine Program Directors

Pre/Post-Test Questions:

1. To diagnose a patient with ABPA (allergic bronchopulmonary aspergillosis), which of the following MUST be present?

    a. Absolute eosinophil count >500
    b. Central bronchiectasis on CT chest
    c. IgG Ab to A. fumigatus
    d. Positive type I skin test for A. fumigatus

2. A 35-year-old female presents to your office for evaluation of dyspnea and wheezing. She has normal chest imaging and reports a previously negative bronchoprovocation study. She is a never-smoker and thus, you are clinically concerned based on her story for possible vocal cord dysfunction. Which of the following is NOT a characteristic finding of vocal cord dysfunction?

    a. Flat inspiratory limb of the flow volume loop on PFTs
    b. Partial bronchodilator responsiveness on PFTs
    c. Adduction of vocal cords on direct laryngoscopy
    d. Intermittent episodes of stridor or upper airway wheeze

3. A 60-year-old male with HIV (CD4 100, intermittently adherent to HAART therapy) presents to evaluate possible asthma and eosinophilia. He also notes some ongoing issues with abdominal pain and diarrhea. He is originally from Guatemala and is a never smoker. You are concerned about possible hematogenous seeding from a helminth infection with Strongyloides and decide the next best course for diagnostic testing should be:

    a. Transbronchial lung biopsy
    b. Surgical lung biopsy
    c. Serial imaging and PFTs
    d. Antibody ELISA testing

© 2023 Association of Pulmonary and Critical Care Medicine Program Directors

© 2023 Association of Pulmonary and Critical Care Medicine Program Directors